



RESENTING CLINICAL SIGNS

History: History of asthma. Radiographs show enlarged cardiac silhouette. No murmur.

DATE

4/8/22

ECHOCARDIOGRAPHIC FINDINGS

2D, M-mode, and Doppler study.

PERFORMED BY:

Kelly Vazquez

Left atrial size is normal. The mitral valve is normal. Left ventricular wall thickness is normal. Left ventricular internal dimensions are normal. Left ventricular systolic function is hyperdynamic. The aorta and aortic valve are normal. Right atrial and right ventricular dimensions are normal. The tricuspid valve is normal. The pulmonary artery and pulmonic valve are normal. No shunting lesions are visualized. No heartworms are visualized. No pericardial effusion or cardiac masses are seen.

INTERPRETED BY

Keith Blass, DVM,
MS, DACVIM
(Cardiology)

LA/Ao - 1.32
IVSd - 4.3 mm
LVPWd - 4.1 mm
LVIDd - 16.8 mm
LVIDs - 5.4 mm
FS - 67.9%
LVOT - 1.08 m/s
RVOT - 1.17 m/s

PATIENT

Keanu Yeaza

ASSESSMENT/RECOMMENDATIONS

Normal echocardiogram

SPECIES

Feline

This examination demonstrates no evidence of structural heart disease. As such, the enlarged cardiac silhouette noted in Keanu's radiographs appears to be a normal variant or artifactual.

BREED

No therapy is recommended based on this exam.

DSH

A recheck echocardiogram is recommended if new physical exam and/or clinical abnormalities suggestive of cardiac dysfunction develop.

SEX

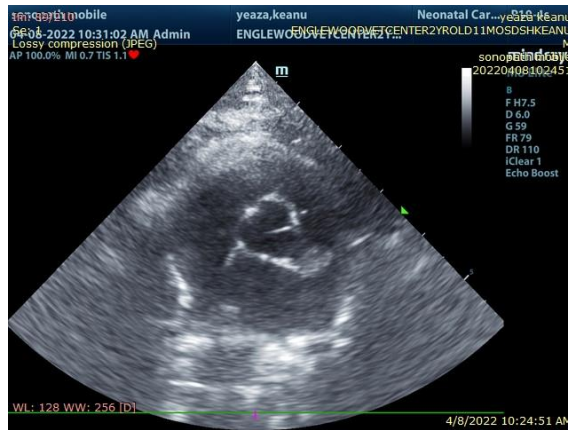
MN

AGE

2 y

WEIGHT

13.8 lb



HOSPITAL NAME

Englewood VC

The information and recommendations provided are based on the images presented by the referring veterinarian. No evaluation can be communicated regarding pathology that was not visible in the image/video clips provided.

REFERRING VET

Dr. Ezik

Thank you for this referral. If the clinical or image interpretation does not parallel your findings or if I can be of any further assistance please contact me.



Keith Blass, DVM, MS, DACVIM (Cardiology)

DATE
KeithBlass@gmail.com
631-804-5754

4/8/22

PERFORMED BY:

Kelly Vazquez

INTERPRETED BY

Keith Blass, DVM,
MS, DACVIM
(Cardiology)

PATIENT

Keanu Yeaza

SPECIES

Feline

BREED

DSH

SEX

MN

AGE

2 y

WEIGHT

13.8 lb

HOSPITAL NAME

Englewood VC

REFERRING VET

Dr. Ezik